


BONUS FEATURE: MICROINCISION CATARACT SURGERY

June 2013 • Volume 8, No. 6

www.crstodayeurope.com 

Cataract & Refractive Surgery

EUROPE **TODAY**

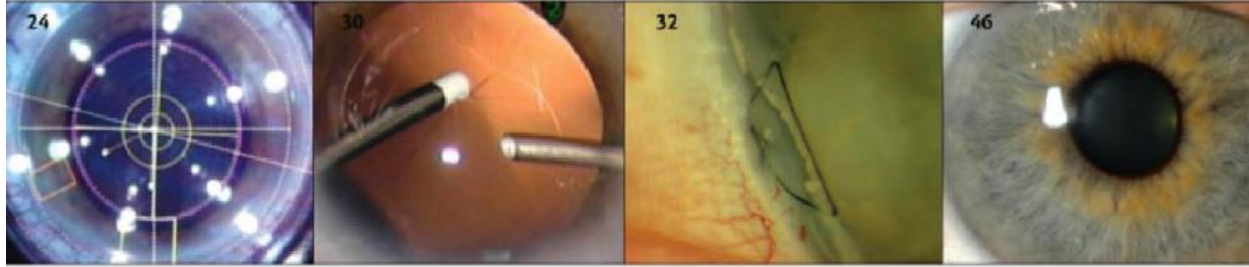


The Cornea Issue

Surgeons decide between traditional surgical approaches, new treatment modalities.

CONCENTRIC INTRASTROMA BOXED SUTURING TECHNIQUE • BENEFITS OF A DISPOSABLE I/A CANNULA

Contents



June 2013 • Volume 8, No. 6

UP FRONT

7 Editor's Page

By Laura Straub, Editor-in-Chief

10 News

ONLINE SURVEY RESULTS

Compiled by Steve Daily, News Editor;
and Callan Navitsky, Senior Editor

15 Medical Updates

Compiled by Callan Navitsky, Senior Editor

INSIDE EYETUBE.NET

18 This Month's Videos on Eyetube.net

CATARACT SURGERY

Bonus Feature: Microincision Cataract Surgery

20 How Small is Too Small? ONLINE SURVEY

By Izzet Can, MD; and Basak Bostanci Ceran, MD

22 My MICS Technique

By Alessandro Franchini, MD

24 Combining MICS and Laser Cataract Surgery

By Jorge L. Alió, MD, PhD; and Felipe A. Soria, MD

Feature Story

30 Benefits of Disposable I/A Cannulas

By Gabor B. Scharioth, MD, PhD;
and Khiun F. Tjia, MD

REFRACTIVE SURGERY

Feature Story

32 Concentric Intrastroma Boxed Suturing Technique

By Meagan Celmer, MD;
and Ming Wang, MD, PhD

COVER STORIES

36 Therapeutic Options to Delay the Need for Corneal Transplant

By Yaron S. Rabinowitz, MD

40 From Penetrating to Lamellar: The Evolution of Keratoplasty

By Donald T. Tan, FRCS, FRCOphth

44 DMEK, DSAEK, or PKP?

By Claus Cursiefen, FEBO

46 DMEK: The New Standard for Lamellar Keratoplasty

By Jack S. Parker, MD; and Gerrit R.J. Melles, MD, PhD

50 Epithelial Thickness: An Indicator for Early Keratoconus?

By A. John Kanellopoulos, MD;
Ioannis M. Aslanides, MD, PhD, MBA, FRCOphth;
and George Asimellis, PhD

56 Subclinical Keratoconus: Detection at Its Earliest Stage

By Damien Gacinel, MD; and Alain Saad, MD

58 Evaluating the Cornea and Ocular Surface

By Massimo Busin, MD; and Elena Albè, MD

62 Enhancing Dry Eye Diagnosis

By Laura Straub, Editor-in-Chief

DEPARTMENTS

64 Innovations

65 Calendar/Ad Index

66 5 Questions With Allon Barsam, MD, MA, FRCOphth

Cover image credit: ©iStockphoto.com/indigart2

How Small Is Too Small?

Incision width is a parameter that directly affects surgical results.

BY İZZET CAN, MD; AND BAŞAK BOSTANCI CERAN, MD

The dream of any cataract surgeon is to carry out surgery using the smallest incision possible, and, if it were an option, using no incision at all. The most popular and widely used small incisions attainable with today's technology seem to be 1.8 and 2.2 mm. Matters of discussion concerning these incisions include which size is more reliable, efficient, and functional, and whether it would be beneficial to use even smaller incisions.

The main advantages of small incisions compared with standard incisions include better anterior chamber control with less trawling of the capsule and, thus, reduced intraoperative complications and expulsive hemorrhage; a shorter healing period; lower risks of wound closure problems, inflammation, and endophthalmitis; less postoperative surgically induced astigmatism (SIA) and higher-order aberrations (HOA); and preservation of the prolate structure and biomechanics of the cornea.¹⁻⁶ If we are unable to fully obtain these advantages with the small incisions we create today, the problem is not the incision itself but the technology we use, which has not evolved to match these incisions.

MICS TECHNIQUES

Microincision cataract surgery (MICS) can be performed with one of two surgical approaches: microcoaxial or biaxial sleeveless MICS. Although surgery can be performed through a 1.8-mm incision with the microcoaxial approach, 2.2 mm is the incision width that has withstood the test of time and is most widely accepted. The biaxial sleeveless approach allows surgeons to complete surgery through 1.2- to 1.4-mm trapezoidal incisions, but for safe IOL implantation one incision is generally enlarged to 1.8 mm.

The primary disadvantage of biaxial MICS is the need for high inflow to preserve anterior chamber stability and, thus, a high bottle height that creates excess turbulence. By contrast, especially with torsional phaco technology, surgeons can use lower phaco parameters with microcoaxial MICS, improving the safety profile and efficiency of this approach.⁷ However, using these low parameters through 1.8-mm incisions does not seem to provide sufficient success with current technology.⁸

SIZE COMPARISON

The best-known advantage of small incisions is the associated reduction of postoperative SIA. In a prospective

comparative study, we found the mean SIAs of 2.8-, 2.2-, and 1.8-mm incisions to be 0.45, 0.24, and 0.13 D, respectively, and these differences were statistically significant.⁷ There are a number of studies in accordance with these results.^{10,11} On the other hand, some authors have indicated no difference in SIA between 1.8- and 2.2-mm incisions.¹² It is important to keep in mind that incision width is not the only factor that affects SIA; proximity of the incision to the optical center can also affect outcomes.

Surgically induced HOAs may be crucially important in the future with the aim of leaving the cornea unaltered. Few studies have investigated the changes in wavefront aberration with different incision sizes.^{13,14} In another prospective study, we saw no change in HOAs with a mean incision width of 1.80 ± 0.09 mm, but significant increases were seen for vertical coma and trefoil in corneal measurements and for primary trefoil in total ocular wavefront analyses with 1.89 ± 0.11 -mm mean incisions.¹⁵ This may suggest that, in order to perform aberration-free surgery, the ideal incision width should be between 1.80 and 1.89 mm.

A number of studies indicate superiority of 1.8-mm incisions for astigmatic and HOA change^{16,17}; however, this incision size has been the subject of debate regarding its integrity and reliability. Studies in the literature show a disparity in results. We conducted a study in which Fourier-domain anterior-segment optical coherence tomography was used to follow dynamic wound-healing processes in eyes that underwent microcoaxial and biaxial surgery with 1.8-mm incisions; our results showed reliable incision integrity and sealing with both techniques; however, these were slightly better with the microcoaxial approach.¹⁸ Moreover, the incidences of wound-healing problems such as endothelial gaps and Descemet membrane detachment were consistent with those in studies using wider incision widths. A few studies have reported problems with wound healing and incision integrity with small incisions. These studies indicated safer wound closure with 2.2-mm incisions, or at least less postoperative edema at the incision site.¹⁹

Surgical efficiency may also be improved by simplifying phacoemulsification, thereby reducing intraoperative complication rates. When 1.8- and 2.2-mm microcoaxial techniques are compared, 2.2-mm incisions seem to provide better results, including decreased effective phaco time (EPT) and total surgery time. Furthermore, the rates of endothelial cell loss and central corneal thickness were

found to be lower after surgeries with 2.2-mm incisions.²⁰

In our previously mentioned study,⁹ when 2.2-mm microcoaxial longitudinal phaco was compared with 1.8-mm biaxial sleeveless phaco, total surgery time was less in the 2.2-mm group, whereas EPT was less in the 1.8-mm group. Moreover, central corneal thickness increase on postoperative day 1, which is an indicator of trauma to surrounding tissues, was lower in the 1.8-mm group. This suggests that, when surgical efficiency is considered, not only the incision width but also the technique itself should be evaluated.

In the past, one of the main factors limiting incision size was IOL technology. Whereas the reliability of IOLs that could pass through microincisions was once problematic, today's technologies have overcome this issue, and the range of IOL options for MICS implantation has expanded. Now a variety of IOLs, including premium lenses, can be inserted through 1.8-mm or slightly smaller incisions. Visual acuity, optical quality, and uveal and capsular biocompatibility with these lenses seem to provide sufficient results.²¹⁻²⁴

As a result, microcoaxial phacoemulsification through a 2.2-mm incision, an approach that is widely preferred by surgeons, seems to offer effective and safe results, especially with the help of technologies such as torsional phacoemulsification, and to provide reliable postoperative incision structure. Moreover, the slight SIA associated with 2.2-mm incisions has a generally negligible effect on postoperative visual function.

CONCLUSION

Underestimating the benefits of small incisions by assuming that their only advantage is reducing or neutralizing SIA would be a mistake. Incision width is a parameter that directly affects surgical results in various ways. When we think of customized IOLs, which may provide personal aberration adjustment in the future, the use of a 1.8- to 1.89-mm incision may seem indispensable, enabling surgery to be performed without changing the cornea.

Microcoaxial technology for 1.8-mm incisions must be improved if this incision width is going to be preferred. Perhaps a sleeveless biaxial technique would be a better alternative, although wound reliability remains controversial. ■

TAKE-HOME MESSAGE

- The best-known, but not the only, advantage of microincisions is the reduction of induced astigmatism.
- When 1.8- and 2.2-mm microcoaxial techniques are compared, 2.2-mm incisions seem to provide better results, including decreased EPT and total surgery time.
- Microcoaxial technology must be improved if a 1.8-mm incision width is to be preferred.

Weigh in on this topic now!



Direct link: <https://www.research.net/s/CRSTE27>

In your opinion, which MICS incision size yields the best results?

- 2.2 mm
 1.8 mm
 Other
 I do not perform MICS

Izzet Can, MD, is a Professor at the Mayagöz Ophthalmic Center in Ankara, Turkey. Professor Can states that he has no financial interest in the products or companies mentioned. He may be reached at e-mail: izzetcan@yahoo.com.

Başak Bostancı Ceran, MD, is with the Antalya Training and Research Hospital Ophthalmology Department in Antalya, Turkey. Dr. Ceran states that she has no financial interest in the products or companies mentioned.

1. Ali İ, Rodriguez-Puig B, Galá A, Ramo M. Outcomes of microincisional cataract surgery versus coaxial phacoemulsification. *Ophthalmology*. 2005;112:1997-2003.
2. Chee S-P, Baxall K. Endothelium after microincision cataract surgery. *J Cataract Refract Surg*. 2002;31:1834-1835.
3. Cavallini GM, Campi L, Masini C, Feloni S, Puppo A. Bimanual microphacoemulsification versus coaxial microphacoemulsification: prospective study. *J Cataract Refract Surg*. 2007;33:387-392.
4. Aho J, Schimchak P, Mentes-Alpar G, Galá A. Retinal image quality after microincision intracapsular lens implantation. *J Cataract Refract Surg*. 2005;31:1557-1560.
5. Elzady B, Aho J, Ortiz D, Montalán R. Corneal aberrations after microincision cataract surgery. *J Cataract Refract Surg*. 2008;34:40-45.
6. Elzady B, Pinaro D, Aho J. Corneal incision quality: microincision cataract surgery versus microcoaxial phacoemulsification. *J Cataract Refract Surg*. 2009;35:466-474.
7. Reischel A, Bagatsis H, Barth T, Wiedemann R. Comparison of endothelial changes and power settings between torsional and longitudinal phacoemulsification. *J Cataract Refract Surg*. 2010;36(11):1855-1861.
8. Christakis PG, Bhoja-Meha RM. Intraoperative performance and postoperative outcome comparison of longitudinal, torsional and transverse phacoemulsification machines. *J Cataract Refract Surg*. 2012;38(2):214-241.
9. Can I, Takmaz T, Yildiz Y, Bayhan HA, Soyugdemir G, Bostancı B. Coaxial, microcoaxial and biaxial microincision cataract surgery: Prospective comparative study. *J Cataract Refract Surg*. 2010;36:740-746.
10. Hansson MK, Gonnemann J, Meier AK, Jovan R, Bettebaum E. Smaller incision size leads to higher predictability in microcoaxial cataract surgery. *Eur J Ophthalmol*. 2013;23(2):202-207.
11. Wilczynski M, Supady L, Lubo P, Synder A, Palanga-Pydy D, Orzeski W. Evaluation of surgically induced astigmatism after coaxial phacoemulsification through 1.8-mm microincision and standard phacoemulsification through 2.75 mm incision. *Acta Otolaryngol*. 2011;131(10-12):114-120.
12. Luo L, Lin H, He M, Gongbin M, Yang Y, Liu Y. Clinical evaluation of three incision size-dependent phacoemulsification systems. *Am J Ophthalmol*. 2012;153(5):831-839.
13. Jiang N, He H, Lu F, Wang Q, Qi L, Zhao Y. Changes in corneal wavefront aberrations in microincision and small-incision cataract surgery. *J Cataract Refract Surg*. 2008;34(12):2095-2098.
14. Demeyer A, Demeyer L, Marotte O, Georges M, Phelip P. Individualized comparative study of corneal and ocular wavefront aberrations after biaxial microincision versus coaxial small-incision cataract surgery. *Br J Ophthalmol*. 2008;92(12):1679-1684.
15. Can I, Bayhan HA, Çelik H, Bostancı Ceran B. Comparison of corneal aberrations after biaxial microincision and microcoaxial cataract surgeries: a prospective study. *Cornea*. 2012;31(1):16-24.
16. Ali İ, Elzady B, Ortiz D. Corneal optical quality following sub-1.8 mm microincision cataract surgery in 2.2 mm microincision coaxial phacoemulsification. *Albany Inst Adv Ophthalmol*. 2010;12:94-99.
17. Nishizawa T, Magawa S, Phelip P. Corneal aberration integrity after microincision cataract surgery: preoperative conditions predict postoperative aberrations. *Br J Ophthalmol*. 2010;94(6):661-665.
18. Can I, Bayhan HA, Çelik H, Bostancı Ceran B. Anterior segment optical coherence tomography evaluation and comparison of main-line corneal incisions in microcoaxial and biaxial cataract surgery. *J Cataract Refract Surg*. 2011;37:490-500.
19. Vinograd V, Vinograd AR, Vinograd VA, Smetana S, Gajjar BI, Mehta S. Incision integrity and postoperative outcomes after microcoaxial phacoemulsification performed using 2 incision-dependent systems. *J Cataract Refract Surg*. 2013;39(4):563-571.
20. Macropaque L, Feroz I, Vecchiario L, Di Nicola M, Mastroianni R. Microcoaxial torsional cataract surgery 1.8 mm versus 2.2 mm: functional and morphological assessment. *Ophthalmol Surg Lasers Imaging*. 2011;42(2):114-124.
21. Aho J, Rodriguez-Puig B, Galá A. Advances in microincision cataract surgery: intracapsular lenses. *Cornea*. 2006;25:90-93.
22. Alvarez B, Fernandez-Yegor L, Senariı A, Montero-Milla I. Prospective study of AcrySulfoflex intracapsular lenses. *J Cataract Refract Surg*. 2007;33:1910-1915.
23. Can I, Takmaz T, Bayhan HA, Bostancı Ceran B. Aspheric microincision intracapsular lens implantation with biaxial microincision cataract surgery: efficacy and reliability. *J Cataract Refract Surg*. 2012;38:1905-1911.
24. Can I, Bostancı Ceran B, Soyugdemir G, Takmaz T. Comparison of clinical outcomes with 2 small-incision multifocal intracapsular lenses. *J Cataract Refract Surg*. 2012;38:60-67.

